Controlled Clinical Trial With Pirfenidone in the Treatment of Breast Capsular Contracture

AQ:1

Evelin Rosaira Veras-Castillo, ●●●, Lazaro Cardenas-Camarena, ●●●,* Ivan Lyra-Gonzalez, ●●●,† Jose Francisco Muñoz-Valle, ●●●,‡ Silvia Lucano-Landeros, ●●●,† Jose Guerrerosantos, ●●●,* Beatriz Gonzalez-Ulloa, ●●●,§ Jose Luis Mercado-Barajas, ●●●,¶ Maria Guadalupe Sanchez-Parada, ●●●,† Ronney Azabache-Wennceslao, ●●●,* and Juan Armendariz-Borunda, PhD†‖*

AQ:2

Background: Breast capsular contracture (BCC) is a commonly adverse event postmammoplastly characterized by an immune response mediated by cytokines and TGF-β1 resulting in excessive synthesis and deposit of extracellular matrix around the breast implant. Presence of TGF-β1 polymorphisms has been associated as a risk factor to develop fibroproliferative diseases.

Methods: This open, controlled, prospective, and pilot clinical trial with 6 months duration was carried out to evaluate the efficacy of 1800 mg a day, of oral Pirfenidone (PFD) in the treatment of BCC (Baker Score III/IV) postmammoplasty. Twenty BCC cases received PFD and 14 BCC control cases underwent capsulectomy after 6 months of enrollment. Both groups were followed up for 6 more months up to 12 months to determine the relapse in the absence of PFD. Determination of TGF-β1 polymorphisms was performed to establish a correlation with capsular contracture.

Results: PFD group experienced BCC-reduction in all breasts 6 months after enrollment. Only 1 of 20 cases relapsed after follow-up. In capsulectomy group, 2 of 14 cases presented progression to grade IV during presurgical period. All capsulectomy cases relapsed at end of follow-up. Nearly hundred percent of all patients studied in this protocol had a profibrogenic homozygous TGF-β1 polymorphism (codon 25; genotype Arg25Arg).

Conclusions: PFD is useful to improve BCC (Baker Score III/IV) postmammoplasty with no relapse after drug administration. There is also an association between capsular contracture and the presence of homozygous G/G TGF-β1 genotype.

Key Words: pirfenodone, breast capsular contracture, TGF beta polymorphysms, Baker Score, antifibrotic therapy

(*Ann Plast Surg* 2011;XX: 000–000)

Currently, breast cancer represents the most common indication for mastectomy with negative influence on personal perception, sexuality, and partnership. Since the introduction of breast implants, silicone, and saline breast implantation have become one of the most common procedures performed by plastic surgeons, not only for aesthetic reasons but also for reconstructive purposes where reconstitution of body image and feelings of attractiveness are important to improve quality of life.[1,2] The use of breast implants is associated with complications, including hematoma, seroma, infection, altered nipple sensation, asymmetry, deflation, and breast capsular contracture (BCC) which is a fact of particular concern to both, patients and surgeons. Different publications address a variable incidence of capsules ranging from 15% to 45% which may result in pain, dissatisfaction with breast appearance, and reoperation, resulting in additional costs to the patient, potential for suboptimal results, and higher probabilities of repeated BCC.[3,4]

Some studies have postulated risk factors for BCC development, like accumulation of tissue fluids in the implant pocket, intensive inflammatory response, subclinical infection, age of the patient, foreign materials, and alteration of cellular and molecular mechanisms in the implantation area.[5–8]

BCC plays a vital role in the host's response to foreign bodies.[9–12] This immunologic response is mediated by cytokines and growth factors such as IL-1, IL-6, TNFα, PDGF, and TGF-β1, activating the fibroproliferative pathway.[13,14]

In previous studies, both human and animal models have been used to prove new therapeutic interventions for breast contracture. Those include antibiotic washes,[15,16] intraluminal steroids,[17,18] submuscular placement,[19] low bleed silicone elastomer shells,[20] systemic antibiotics,[21] underfilling implants, and saline-filled implants.[22,23] Unfortunately, most of these therapeutic strategies have no significant response and show high rate relapse.[24–26]

Pirfenidone (PFD) is a new wide-spectrum antifibrotic drug that modulates diverse cytokines action, that is, TGF-β, TNF-α, EGF, PDGF, VEGF, IGF-1, FGF, IFN-γ, IL-1, IL-6, and IL-8; and it has shown promising effects in both, in vitro and in vivo settings in the prevention and regression of pulmonary fibrosis, peritoneal sclerosis, hepatic cirrhosis, uterine fibromyoma, renal interstitial fibrosis, and hypertrophic scars in experimental and human studies.[27] We recently published that oral PFD is able to prevent the formation of capsular contraction when female rats were subjected to mammary implantation.[28] AQ:3

On the other hand, previous studies have correlated the presence of specific TGF-β1 polymorphisms with a risk factor to develop and exacerbate fibrosis in liver,[29–31] lung,[32] and hypertrophic scarring.[33] These and other reports, support the hypothesis that homozygous G/G TGF-β1 polymorphisms are commonly associated with fibroproliferative ailments.

In this controlled clinical trial, we evaluated the efficacy of PFD in the treatment of BCC postmammoplasty as compared with a group of BCC patients who did not received the medication (capsulectomy). Also, the presence of homozygous G/G TGF-β1 polymorphism and its association with the development and evolution of BCC was evaluated. Thus, for this purpose, we included a control group of 30 subjects who underwent a breast implant without developing BCC.

Received March 11, 2011, and accepted for publication, after revision May 2, 2011.

From the *Instituto Jalisciense de Cirugía Reconstructiva "Dr. José Guerrerosantos," Guadalajara, Jalisco, Mexico; †Instituto de Biología Molecular en Medicina y Terapia Génica, CUCS, Universidad de Guadalajara, Guadalajara, Jalisco, Mexico; ‡IIRSME, CUCS, Universidad de Guadalajara, Guadalajara Jalisco, Mexico; §Diagnóstico Especializado por Imagen DEI, Zapopan, Jalisco, Mexico; ¶Departamento de Ciencias Sociales, CUCS, Universidad de Guadalajara, Guadalajara, Jalisco, Mexico; and ‖OPD Hospital Civil de Guadalajara, Guadalajara, Jalisco, Mexico. AQ:23

Reprints: Juan Armendariz-Borunda, Department of Molecular Biology and Genomics, CUCS, University of Guadalajara, Sierra Mojada # 950, Guadalajara, Jalisco 44281, Mexico. E-mail: armdbo@gmail.com.

ISSN: 0148-7043/11/0000-0001
DOI: 10.1097/SAP.0b013e31822284f4

<DOI: 10.1097/SAP.0b013e31822284f4>

MATERIALS AND METHODS

Study Design

This open, controlled, prospective, and pilot clinical trial was designed to be carried for 6 months duration to evaluate the efficacy of PFD (1800 mg) [5-methyl-1-phenyl-2-(1H)-pyridone] taken AQ:4 orally daily in the treatment of BCC postmammoplasty. The medication was administered 3 times a day in the form of 600-mg prolonged-release tablets manufactured according to standard GMPs, GLPs, and sanitary regulations enforced by COFEPRIS AQ:5 (Mexican Minister of Health).

In the same line of reasoning, we evaluated the presence of a specific TGF-β1 polymorphism in our study group as a risk factor to develop BCC.

Regulatory Authorities and Ethics Committees from the Instituto Jalisciense de Cirugía Reconstructiva approved the conduction of this protocol (along with patient sheets and consent forms) with the registry number 01/09. Also, this study was undertaken in accordance with the Declaration of Helsinki and with the local laws and regulation applicable to the use of a new therapeutic agent in México.

All patients included were recruited from Instituto Jalisciense de Cirugia Reconstructiva. This institute is a concentration center for these kind of disorders, which provides specialized medical care to patients from neighboring states of Jalisco in which the city of AQ:6 Guadalajara.

Previous initiation of the protocol, consent forms were signed for all patients enrolled in the study.

Study Group

Seventeen patients with clinical and ultrasonographic diagnosis of BCC were included. Fourteen patients displayed unilateral BCC and 3 of them had bilateral contracture, for a total of 20 breasts affected. They were enrolled for treatment with 600-mg PFD in the form of prolonged-release tablets 3 times a day for 6 months, to evaluate the drug effect on the capsular tissue. Patients were clinically monitored on monthly basis and after 6 months of treatment, the planned primary end-points were determined clinically by using the Baker Score and radiologically by ultrasonography (USG) assessment. An additional follow-up of 6 months in which no drug was administered was carried out to evaluate the possibility of BCC relapse.

Seventeen females aged 21 to 58 years (mean age = 41.19, SD ± 11) who presented severe BCC by Baker Score (grade III/IV) were included in this study group. All patients included had a BCC evolution of more than 1 year. All patients had normal laboratory values for hepatic, renal, and serum levels at the beginning of the protocol and were followed up during the time of the study.

No infection, seroma, or hematoma was reported in any of the patients during the postoperative period (30 days). At the end of 12 months (6 months on PFD and 6 more months of follow-up with no PFD), all analyses were performed as indicated below.

Exclusion criteria applied to subjects whom voluntary withdraw from the study. Also important clinical abnormalities were cause of exclusion as well as violation of protocol or by investigators' decision due to medical or nonmedical reasons. Patients in Baker Score I and/or II were not included due to the fact that would be difficult to test the efficacy of PFD in the potential reversal of severe BCC. It would be difficult to rule out the possible spontaneous regression. Furthermore, patients in Baker Score I and II are difficult to find, since they do not have discomfort or symptoms suggestive of development of complications, and therefore, do not attend the clinician.

Control Capsulectomy Group

Thirteen patients were enrolled in this group because they chose not to take PFD. Instead, they decided to undergo capsulectomy, knowing they had to wait for this surgical procedure to take place. Twelve patients displayed unilateral BCC and 1 had bilateral contracture, for a total of 14 breasts affected. Control group was composed by females aged 23 to 56 years (mean age, 40.14 SD ± 8.69). All these patients also presented severe unilateral BCC by Baker Score (grade III/IV). All patients included had a BCC evolution of more than 1 year and had normal laboratory values for hepatic, renal, and serum levels at the beginning of the protocol, and were followed up for 6 months, time in which they did not receive PFD. They received only support therapy. Patients were clinically evaluated on monthly basis, and at the end of 6 months, primary end-points were evaluated clinically and radiologically as for the PFD group.

Furthermore, these patients underwent a capsulectomy to relieve the pain and breast capsular contraction and they were followed up for additional 6 months to evaluate potential BCC relapse. AQ:7

As in the PFD group, no observation for infection, seroma, or hematoma was noted in any of patients during postoperative period (30 days).

BCC Ultrasonographic Assessment

Three USG breast assessments with emphasis on BCC were performed during the study: one at the beginning, the second one at the end of the first 6 months with or without PFD, and the last one at the end of follow-up (12 months). To diagnose BCC, a qualified radiologist in breast imaging performed the examination. Parameters evaluated in 4 quadrants included capsule's anteroposterior diameter (APD) and capsular thickness. This procedure was carried out comparing the thickness measurements with radiologic parameters. Besides, a clinical/radiologic correlation of thickness versus Baker Score was established as described by Zahavi et al.[34] In addition, free liquid in the capsule, and signs of retraction or capsular rupture were evaluated by curved or linear transducers of 5 to 12 MHz.

BCC Clinical Assessment

Experienced evaluators including plastic surgeons and breast imaging radiologists independently graded each breast. Clinical assessment was made on monthly basis for a period of 12 months, using Baker Score to evaluate deformation, texture by palpation, and tenderness from each breast (Table 1). Digital photographs of the T1, AQ:8-9 examined breasts were also taken for documentation purposes.

TGF-β1 Polymorphism Screening

Blood samples from all patients enrolled in this protocol were obtained to get genomic DNA and carry out determinations of genetic markers (TGF-β1 polymorphism in codon 25). The G to C transition [G915C (Arg25Pro)] was identified by digestion with *Bgl*-I (New England Biolabs, Ipswich, MA). The G allele yields fragments of 131, 103, and 60 bp; the C allele yields fragments of 131 and 163 bp. The 10-μL aliquots of amplicons were digested in the

TABLE 1. Baker Score[35]

	Hardness	Implant Palpation	Implant Visibility
Grade I	Soft	No palpable	No visible
Grade II	Minimum	Palpable	No visible
Grade III	Moderate	Easily palpable	Distortion
Grade IV	Severe	Hard, painful, and cold	Severe distortion

TABLE 2. Genotype Frequencies and Allelic Distribution of TGF-β1 Arg25Pro Polymorphism in BCC Patients and Control Group With Breast Implant

	TGF-β1 (Arg25Pro)			
	BCC Patients (n = 30)		Control Group (n = 30) Breast Implant Group Frequency (%)	
	PDF Group (n = 17) Frequency (%)	Capsulectomy Group (n = 13) Frequency (%)		*P**
Genotype				0.0001
G/G	15 (88)	13 (100)	5 (17)	
G/C	2 (12)	0 (0)	25 (83)	
C/C	0 (0)	0 (0)	0 (0)	
Allele				
G	32 (94)	26 (100)	35 (58)	
C	2 (6)	0 (0)	25 (42)	

*BCC patients versus control group.

following reaction mix: 1-μL buffer, 0.5-μL Bgl-I, 7.5-μL H2O, 1-μL PCR product. The amplicons were digested for 3 hours at 37°C. AQ:10

A group of 30 patients who underwent breast implantation and did not develop BCC was included as a control to search for frequencies of homozygosity or heterozygosity for codon 25 in TGF-β1 gene. The genotype frequencies and allelic distribution of TGF-β1 Arg25Pro are given in Table 2. T2, AQ:11

PCR Parameters

Standard 25-μL reactions contained 2.5-μL (1×) reaction buffer, 2.25-μM (4.5 mM) MgCl2, 2.0-μL (0.2 mM) dNTPs, 2.5-μL (0.3 μM) forward primer, 2.5-μL (0.3 μM) reverse primer, 0.25-μL (0.05 U/μL) diluted *Taq* polymerase, 8-μL (1.6 M) betaine, 1.5-μL (6%) DMSO, 0.2-μL genomic DNA, and 3.3-μL H2O.

Amplification was carried out in a Robocycler using cycle parameters of 10 minutes at 96°C, 62°C, and 73°C (75-second segments), and a final extension for 5 minutes at 73°C. The reactions were carried out in Stratagene 200-μL capped tubes since these gave optimal heat transfer in the Robocycler. The PCR generated amplicons with a fragment size of 294 bp.[36]

Drug Administration

PFD (600-mg) prolonged-release tablets (Lot. No IDE 0906001, CTT) was orally administrated to the study group t.i.d. (every 8 hours), 20 minutes after meals during 6 months. Patient's compliance was closely monitored with drug registration sheets. Drug-related adverse events were monitored through-out the study. AQ:12

Statistical Analysis

Statistical analysis of variables was tested by Wilcoxon paired samples and Mann-Whitney *U*, where Baker Score was compared between both groups (PFD and Capsulectomy group). Confidence interval used in this study was 95%. These studies were conducted using SPSS 17 for Windows to analyze the data.

RESULTS

Efficacy of PFD

Treatment of the 20 breasts was initiated with a capsular contracture with an evolution of 14.4 months average and received 600-mg PFD t.i.d. for 26 weeks (6 months). AQ:13

As indicated in methods section, cases were clinically evaluated on monthly basis; and by USG at the beginning, at the end of PFD administration (6 months), and at the end of the follow-up (12 months). All cases included in the study showed improvement in the degree of BCC.

At the end of PFD administration, we found that in 14 cases (70%) no clinical or sonographic evidence of BCC (NCSECC) was detected (Baker Score no detectable).

Important to mention that of those 14 cases, 9 (45%) were initially graded as III and 5 (25%) were graded as IV at the beginning of the study. This fact showed that no matter the degree of BCC, fibrotic tissue in the capsule could be degraded by PFD treatment, as we have previously demonstrated in experimental models.[26] The remaining 6 cases from the initial 20 (30%), presented initial grade IV BCC with a reduction, in 1 case (5%) to grade II, and 5 cases (25%) from grade IV to grade III. AQ:14

At the end of follow-up (6 more months without PFD), we found that 19 patients (95%) showed no clinical or sonographic BCC relapse.

Only 1 case (5%), which at the beginning of the treatment was grade IV and at the end of PFD administration showed NCSECC-(Baker Score no detectable), presented recurrence from NCSECC to grade III, attributed to steroid use and excessive exercise. AQ:15

In this study, results showed that all patients included with a grade III by Baker Score treated with 600 mg PFD t.i.d. obtained a regression of their BCC down to NCSECC (Baker Score No detectable) ($P < 0.001$) Figure 1. A representative photograph of a patient treated with PFD is shown in Figure 2. F1 F2

Figure 2 shows that breasts involved in bilateral BCC responded in a variable way as compared with patients with unilateral BCC. Figure 3 shows the dramatic response of right breast scored IV by Baker Score and how it diminished to NCSECC after 6 months of PFD (refer to case 11 in Fig. 1). F3

Ultrasonographic Findings

In all patients, the initial sonographic evaluation before PFD administration, reported BCC with characteristics as increased APD and thickness of the capsule, free capsular liquid, and mammary retraction.

Six months after the administration of PFD (1800 mg) on daily basis, a gradual reduction of the APD and thickness of the capsule in 19 cases (95%) was noticed. Ultrascans were performed by a trained breast radiologist at 6 and 12 months of the study. Statistical analysis showed the analysis of APD with an important statistical significance ($P < 0.001$) between beginning of the protocol and 6 months of treatment. As expected, no statistical significance was found between 6 to 12 months (follow-up), indicating, again, no BCC relapse (Table 3). T3

In a comparison of capsular thickness by quadrants, *P* was significant in each case as shown in Table 4. Notably, the only case that showed recurrence of the contracture (5%) showed an increase in those parameters in the period from 6 to 12 months. T4

Two cases (10%) that went from grade IV to III, showed retraction and mild subcapsular fluid at the end of the study.

Noteworthy, there was no difference in capsular thickness between subglandular and submuscular location.

Control Capsulectomy Group

Fourteen breasts in 13 patients aged between 23 and 55 years with an average BCC grade III/IV by Baker mScore were enrolled into the control group and continue their natural progression of BCC until performance of capsulectomy as scheduled (see the section "Control Capsulectomy Group" of Material and Methods). These patients received only symptomatic treatment during the 6 months of presurgical period. AQ:16

Of the 14 breasts, 8 had a Baker Score of III, whereas 6 of them were enrolled with an initial Baker Score of IV. Our findings AQ:17

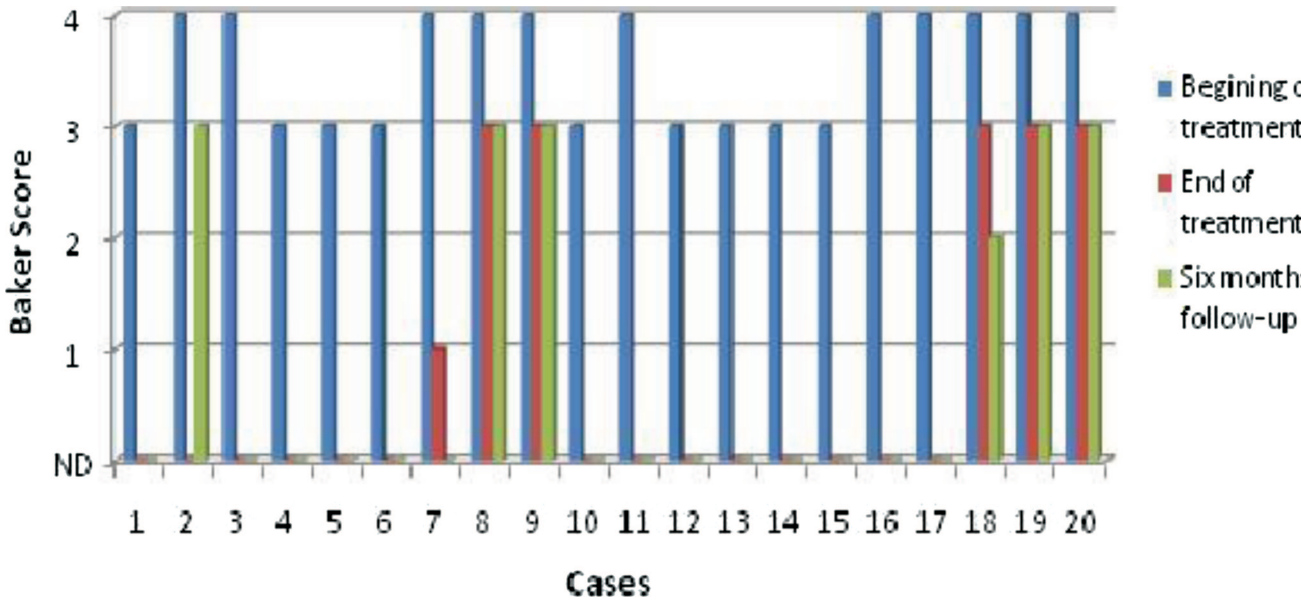

FIGURE 1. Comparison between cases treated with PFD. All patients showed important improvement at the end of PFD administration. Follow-up demonstrated only 1 case with relapse. Baker Score no detected equals NCSECC.

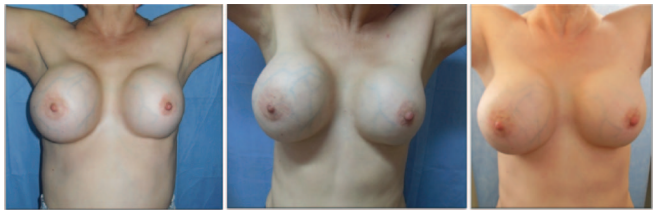

FIGURE 2. Patient with diagnosis of bilateral Breast Capsular Contracture. Left panel shows right breast with grade IV and left breast with grade III; Middle panel shows same patient 6 months after treatment with PFD where is clearly noted that BCC in left breast dropped down to NCSECC, and right breast diminished to grade III. Right panel shows the follow-up of the same patient after 6 months without PFD, where no BCC relapse in either breast was noticed.

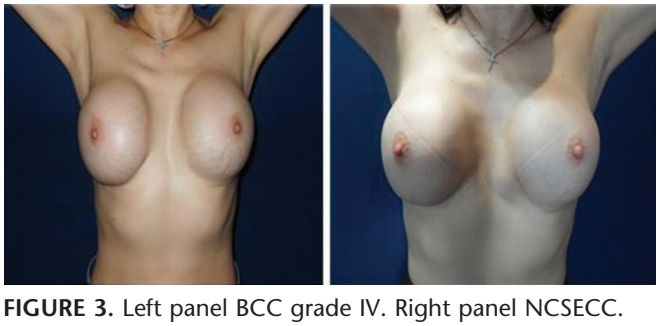

FIGURE 3. Left panel BCC grade IV. Right panel NCSECC.

proved that despite the symptomatic treatment, a notable BCC progression was evident. Thus, 2 breasts grade III at enrollment time, progressed to grade IV 6 months after when they underwent capsulectomy. The other 12 breasts remained at the same BCC scoring.

Importantly, every single breast which had capsulectomy (n = 14), developed BCC again after 6 months follow-up postsurgery.

TABLE 3. Differences Between Anteroposterior Diameter (APD) by USG at the Beginning, End of Treatment and After Follow-up*

	Beginning APD [cm]	APD End of Treatment [cm] (6 mo)†	APD After Follow-up [cm] (12 mo)‡
Mean	7.57	6.425	6.085
SD	2.159	2.319	2.062

*Analyses were conducted using T for related samples.
†P = <0.001 between beginning of treatment and 6 mo after PFD.
‡P = NS between 12 mo of follow-up and 6 mo of PFD.

Seven of these patients presented BCC grade II, 5 of them developed grade III and 2 patients grade I.

Figure 4 shows a representative photograph of the only capsulectomy patient with bilateral BCC. F4

Statistical Improvement

Wilcoxon analysis for related samples was performed to evaluate the relapse of BCC comparing beginning of protocol versus 12 months of follow-up. A significant difference in both, PFD group (P = 0.0001) and Capsulectomy group (P = 0.001) was found. Although only in 1 of 20 breasts studied in PFD group experienced relapse, 14 in capsulectomy group underwent BCC recurrence.

Also, using Mann-Whitney U test, we compared both groups at the end of 12 months follow-up. Results showed a favorable significance (P = <0.006) to PFD group (Table 5). AQ:18 T5

Association of TGF-β1 Polymorphism and BCC

Patients with BCC represent an important population affected by several degrees of fibrosis, manifested by capsular thickness augmentation. Table 2 shows genotype frequencies analyses in PFD group. Remarkably, 15 patients (88%) had the homozygous G/G TGF-β1 genotype (codon 25; genotype Arg^{25}/Arg^{25}), and negligibly, only 2 patients (12%) showed heterozygosity with G/C TGF-β1 genotype. All 13 patients enrolled in control capsulectomy group displayed homozygous G/G genotype. None of them displayed the AQ:19

TABLE 4. Differences in Capsular Thickness by Quadrant After 6 mo of PFD*

	Capsule Thickness ESQ		Capsule Thickness ISQ		Capsule Thickness EIQ		Capsule Thickness IIQ	
	Beginning	Ending	Beginning	Ending	Beginning	Ending	Beginning	Ending
Mean	1.505	1.18	1.6	1.19	1.775	1.185	1.86	1.115
SD	0.464	0.472	0.681	0.518	1.062	0.474	1.280	0.446
	$P = 0.001$		$P = 0.001$		$P \leq 0.005$		$P \leq 0.01$	

Capsular Contracture = Fibrous Capsule ≥1.42 mm according to Zahavi et al.[34]
*Expressed in millimeters.
ESQ indicates external superior quadrant; ISQ, internal superior quadrant; EIQ, external inferior quadrant; IIQ, internal inferior quadrant.

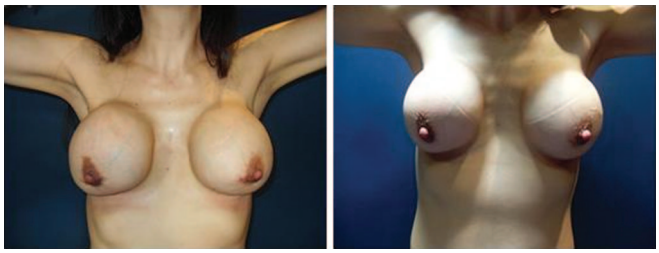

FIGURE 4. Patient with diagnosis of bilateral breast capsular contracture treated with capsulectomy. Left panel shows both breasts with grade IV BCC at time of enrollment before capsulectomy; right panel shows the follow-up of the same patient after 6 months postcapsulectomy, where right breast presented a BCC relapse grade III, and left breast relapsed to grade II.

TABLE 5. BCC Comparative at the Beginning and 12-mo Follow-up in Both Groups

	Baker Score		
Group	Beginning Mean (Range)	12 mo of Follow-up Mean (Range)	*P**
PFD (n=20)	4 (3–4)	0.5 (0–3)	0.0001
Capsulectomy (n=14)	4 (3–4)	2 (1–3)	0.001
$P^{\dagger}$	NS	≤0.006	

Statistical analysis results.
*Wilcoxon for paired samples.
†Mann-Whitney *U*.
NS indicates nonsignificance.

wild-type C/C genotype. In other words, 188% of 200% of our female patients included in this study carried a specific genomic mark for fibroproliferative disorders.

Importantly, 25 of 30 subjects (83%) who underwent breast implant surgery and did not develop BCC, showed a heterozygous G/C TGF-β1, suggesting a correlation of their genomic make-up with the diminished tendency of these women to develop BCC.

These evidences are relevant because, as far as we know, no study has described an association of homozygous G/G (Arg25Arg) TGF-β1 polymorphism in codon 25 with capsular contracture.[37,38]

DISCUSSION

The goal of this study was to evaluate PFD effectiveness in BCC improvement.

Historically, BCC represents one of the most common complications in both, reconstructive and aesthetic breast implant collocation. Surgery, specifically capsulectomy which involves the complete removal of the capsule has been used as the conventional and more effective treatment for this complication until now. Therefore we chose this procedure as the standard to be compared with PFD. However, high rates of regression that may be even worse than the primary lesion represent one of the most difficult challenges for the plastic surgeon.

As we exposed before, focus in the cellular and fibrillar component of the capsula brings the opportunity to search for new therapeutic options. Recent histologic studies have revealed the inflammatory reaction around the mammary implant, which derives in a fibrotic contracture that encapsulates the foreign body.[6,7,39] These reactions explain relapse even postcapsulectomy and implant replacement.

Different studies have used leukotriene antagonists as therapeutic measures, but their principal effect have been observed in BCCs grades I and II as determined with Baker Score.[40] Other approaches have focused on the use of acellular dermal matrix which has proved some capacity to prevent capsule formation, but still in study in animal models.[41]

PFD is an antifibrotic, cytokine, and extracellular matrix (ECM) degradation modulator. It is known that PFD downregulates a number of profibrogenic and proinflammatory cytokines, along with its ability to upregulate matrix metalloproteinases at both, gene and protein levels.[27] Our previous studies[28] in experimental models of mammary transplant demonstrated that a daily oral dose of PFD was able to prevent the formation of capsule contracture. Thus, PFD could represent a plausible option to prevent, stop, and avoid formation and/or relapse of BCC.

In this controlled clinical trial, we evaluated the use of PFD to obtain breast capsular reversion compared with control group, which was treated in a standard way with capsulectomy. The results we obtained proved that all PFD patients registered a variable degree of improvement. Most of them got a BCC reversion down to NCSECC with no need of surgery.

PFD group experienced BCC-reduction in all breasts 6 months after enrollment. Only 1 of 20 cases relapsed after follow-up. In capsulectomy group, 2 cases of 14 presented progression to grade IV during presurgical period. All capsulectomy cases relapsed at end of follow-up. Therefore, PFD is useful to improve BCC (Baker Score III/IV) postmammoplasty with no relapse after drug administration.

Previous studies realized by our group[42] and others,[43] have demonstrated that PFD is useful in the treatment of fibroproliferative disorders such as liver and lung human fibrosis. In the clinical trial, we conducted for hepatic fibrosis, a dose of 1200 mg PFD a day was used with good results.[42] Azuma et al[43] reported an improvement in patients with pulmonary fibrosis after 6 to 12 months of a daily dose of 1800 mg. We have based our decision of using 1800 mg of PFD

in this clinical trial for BCC in those previous observations. Furthermore, the pharmaceutical manufacturing of 600-mg prolonged-release tablets of PFD used in this study allowed us to ensure a constant bioavailability of the drug.

The radiologic assessment of the patients showed an important and progressive reduction of the capsular thickness and the regression of the natural form of the breast implant as a clinical AQ:20 expression of the cellular action of PFD.

Having in mind that this is a fibrotic process located in the breast produced by a foreign body implantation, and the evidence of association of TGF-β1 polymorphisms with fibrotic diseases like liver cirrhosis,[29] cystic fibrosis,[44] and idiopathic pulmonary fibrosis,[32] we searched for a single nucleotide polymorphism in codon 25 of the gene resulting in an amino acid substitution (Arg/Pro). A very important observation of this study is the fact that most of patients studied (28 of 30) had a homozygous G/G TGF-β1 genotype (Arg25Arg) profibrogenic TGF-β1 polymorphism. This finding suggests that there is also an association between capsular contracture and the presence of genetic polymorphisms of TGF-β1. Comparably, a set of control subjects with no BCC demonstrated that the AQ:21 predominant TGF-β1 genotype was a heterozygous G/C.

The advantage of PFD over capsulectomy was evident. PFD patients avoided capsulectomy and were saved from all complica- AQ:22 tions that come with the procedure. Clinical and USG assessment showed persistence of results even 6 months after treatment. Our results showed that breasts with Baker Score III/IV responded properly to PFD administration no matter time of evolution, implant surface or site of collocation. Finally, PFD side effects were minor and presented only in 20% to 25% of patients. Minor side effects like photosensitivity, nausea, vomiting, and gastric discomfort resolved after 2 to 3 months of intake.

We propose the use of PFD in the initial treatment of BCC.

REFERENCES

1. Rowland JH, Desmond KA, Meyerowitz BE, et al. Role of breast reconstructive surgery in physical and emotional outcomes among breast cancer survivors. *J Natl Cancer Inst*. 2000;92:1422–1429.
2. Cunningham B. Update on situation of breast implants in the U.S. presented at EQUAM's 3rd Consensus Conference, Regensburg, Germany, 1998.
3. Ersek RA. Rate and incidence of capsular contracture: a comparison of smooth and textured silicone double-lumen breast prostheses. *Plast Reconstr Surg*. 1991;87:879–884.
4. Barnsley GP, Sigurdson LJ, Barnsley SE. Textured surface breast implants in the prevention of capsular contracture among breast augmentation patients: a meta-analysis of randomized controlled trials. *Plast Reconstr Surg*. 2006;117:2182–2190.
5. Siggelkow W, Faridi A, Spiritus K, et al. Histological analysis of silicone breast implant capsules and correlation with capsular contracture. *Biomaterials*. 2003;24:1101–1109.
6. Dolores W, Rainer C, Niederegger H, et al. Cellular and molecular composition of fibrous capsules formed around silicone breast implants with special focus on local immune reactions. *J Autoimmunity*. 2004;23:81–91.
7. Ulrich D, Lichtenegger F, Eblenkamp M, et al. Matrix metalloproteinases, tissue inhibitors of metalloproteinases, aminoterminal propeptide of procollagen type III, and hyaluronan in sera and tissue of patients with capsular contracture after augmentation with Trilucent breast implants. *Plast Reconstr Surg*. 2004;114:229–236.
8. Wyatt LE, Sinow JD, Wollman JS, et al. The influence of time on human breast capsule histology: smooth and textured silicone-surfaced implants. *Plast Reconstr Surg*. 1998;102:1922–1931.
9. Loosing C, Hanson HA. Peptide growth factor and myofibroblast in capsules around human breast implants. *Plast Reconstr Surg*. 1993;91:1277–1286.
10. Vistnes LM, Ksander GA, Isaacs G, et al. Elevated glycosaminoglycans and chondroitin 4-sulfate and other properties of contracted human prosthesis capsules. *Ann Plast Surg*. 1981;7:195–203.
11. Prantl L, Schreml S, Fichtner-Feigl S, et al. Clinical and morphological conditions in capsular contracture formed around silicone breast implants. *Plast Reconstr Surg*. 2007;120:275–284.
12. Gabriel SE, Woods JE, O'Fallon WM, et al. Complications leading to surgery after breast implantation. *N Engl J Med*. 1997;336:677–682.
13. Kuhn A, Singh S, Smith PD, et al. Periprosthetic breast capsules contain the fibrogenic cytokines TGF-β1 and TGF-β2, suggesting possible new treatment approaches. *Ann Plast Surg*. 2000;44):387–391.
14. Brohim RM, Foresman PA, Hildebrandt PK, et al. Early tissue reaction to textured breast implant surfaces. *Ann Plast Surg*. 1992;28:354–362.
15. Schreml S, Heine N, Eisenmann-Klein M, et al. Bacterial colonization is of major relevance for high-grade capsular contracture after augmentation mammaplasty. *Ann Plast Surg*. 2007;59:126–130.
16. Burkhardt BR, Dempsey PD, Schnur PL, et al. Capsular contracture: a prospective study of the effect of local antibacterial agents. *Plast Reconstr Surg*. 1986;77:919–932.
17. Caffee HH. Intracapsular injection of triamcinolone for intractable capsule contracture. *Plast Reconstr Surg*. 1994;94:824–828.
18. Lemperle G, Exner K. Effect of cortisone on capsular contracture in double-lumen breast implants: ten years' experience. *Aesthetic Plast Surg*. 1993;17:317–323.
19. Vazquez B, Given KS, Houston GC. Breast augmentation: a review of subglandular and submuscular implantation. *Aesthetic Plast Surg*. 1987;11:101–105.
20. Chang L, Caldwell E, Reading G, et al. A comparison of conventional and low-bleed implants in augmentation mammaplasty. *Plast Reconstr Surg*. 1992;89:79–82.
21. Van Heerden J, Turner M, Hoffmann D, et al. Antimicrobial coating agents: can biofilm formation on a breast implant be prevented? *J Plast Reconstr Aesthet Surg*. 2009;62:610–617.
22. Gutowski KA, Mesna GT, Cunninghan BL. Saline-filled breast implants: a Plastic Surgery Educational Foundation multicenter outcomes study. *Plast Reconstr Surg*. 1997;100:1019–1024.
23. Spear SL, Elmaraghy M, Hess C. Textured-surface saline-filled silicone breast implants for augmentation mammaplasty. *Plast Reconstr Surg*. 2000;105:1542–1552.
24. Tamboto H, Vickery K, Deva AK. Subclinical (biofilm) infection causes capsular contracture in a porcine model following augmentation mammaplasty. *Plast Reconstr Surg*. 2010;126:835–842.
25. Zimman OA, Toblli J, Stella I, et al. The effects of angiotensin-converting-enzyme inhibitors on the fibrous envelope around mammary implants. *Plast Reconstr Surg*. 2007;120:2025–2030.
26. Adams WP Jr, Haydon MS, Raniere J Jr, et al. A rabbit model for capsular contracture: development and clinical implications. *Plast Reconstr Surg*. 2006;117:1214–1219.
27. Macias-Barragan J, Sandoval-Rodriguez A, Navarro-Partida J, et al. The multifaceted role of pirfenidone and its novel targets. *Fibrogenesis Tissue Repair*. 2010;1:3–16.
28. Gancedo M, Ruiz-Corro L, Salazar-Montes A, et al. Pirfenidone in capsular contracture after mammary implantation. *Aesthetic Plast Surg*. 2008;32:32–40.
29. Armendariz-Borunda J, Rincon AR, Muñoz-Valle JF, et al. Fibrogenic polymorphisms (TGF-beta, PAI-1, AT) in Mexican patients with established liver fibrosis. Potential correlation with pirfenidone treatment. *J Investig Med*. 2008;56:944–953.
30. Powell EE, Edwards-Smith CJ, Hay JL, et al. Host genetic factors influence disease progression in chronic hepatitis C. *Hepatology*. 2000;31:828–833.
31. Tag CG, Mengsteab S, Hellerbrand C, et al. Analysis of the transforming growth factor-beta 1 (TGF-beta1) codon 25 gene polymorphism by light cycle analysis in patients with chronic hepatitis C infection. *Cytokine*. 2003;24:173–181.
32. Xaubet A, Marin-Arguedas A, Lario S, et al. Transforming growth factor-beta 1 gene polymorphisms are associated with disease progression in idiopathic pulmonary fibrosis. *Am J Respir Crit Care Med*. 2003;168:431–435.
33. Bayat A, Bock O, Mrowietz U, et al. Genetic susceptibility to keloid disease and hypertrophic scarring: transforming growth factor beta1 common polymorphisms and plasma levels. *Plast Reconstr Surg*. 2003;111:535–543.
34. Zahavi A, Sklair ML, Ad-El DD. Capsular contracture of the breast: working towards a better classification using clinical and radiologic assessment. *Ann Plast Surg*. 2006;57:248–251.
35. Baker JL Jr. *Augmentation Mammaplasty: Symposium on Aesthetic Surgery of the Breast.* St Louis, MO: C. V. Mosley Company; 1978;256–263.
36. Wood NA, Thomson SC, Smith RM, Bidwell JL. Identification of human TGF-β1 signal (leader) sequence polymorphisms by PCR-RFLP. *J Immunol Methods*. 2000;234(1–2);117–122.
37. Oliver J, Agundez JA, Morales S, et al. Polymosrphisms in the transforming

growth factor-beta gene (TGF-beta) and the risk of advanced alcoholic liver disease. *Liver Int*. 2005;25:935–939.

38. Wang H, Mengsteab S, Tag CG, et al. Transforming growth factor-beta 1 gene polymorphisms are associated with progression of liver fibrosis in Caucasians with chronic hepatitis C infection. *World J Gastroenterol*. 2005; 11:1929–1936.
39. D'Andrea F, Nicoletti GF, Grella E, et al. Modification of cysteinyl leukotriene receptor expression in capsular contracture. *Ann Plast Surg*. 2007;58: 212–214.
40. Huang CK, Handel N. Effects of Singulair (montelukast) treatment for capsular contracture. *Aesthet Surg J*. 2010;30404–408.
41. Stump A, Holton LH III, Connor J, et al. The use of acellular dermal matrix to prevent capsule formation around implants in a primate model. *Plast Reconstr Surg*. 2009;124:82–91.
42. Armendariz-Borunda J, Islas-Carbajal MC, Meza-Garcia E, et al. A pilot study in patients with established advanced liver fibrosis using pirfenidone. *Gut*. 2006;55:1663–1665.
43. Azuma A, Nukiwa T, Tsuboi E, et al. Double-blind, placebo-controlled trial of pirfenidone in patients with idiopathic pulmonary Fibrosis. *Am J Respir Crit Care Med*. 2005;171:1040–1047.
44. Brazova J, Sismova K, Vavrova V, et al. Polymorphisms of TGF-beta1 in cystic fibrosis patients. *Clin Immunol*. 2006;121:350–357.

AUTHOR QUERIES

AUTHOR PLEASE ANSWER ALL QUERIES 1

AQ1—Please confirm whether the short title is OK as given.

AQ2—Please provide the degree(s)/educational qualification for all the authors.

AQ3—Please expand TGF, TNF, EGF, PDGF, VEGF, IGF-1, FGF, IFN, and IL in the text.

AQ4—Please check whether the edit conveys the intended meaning.

AQ5—Please expand COFEPRIS, GMPs, and GLPs in the text.

AQ6—Please check whether the edit conveys the intended meaning.

AQ7—Please check whether the edit conveys the intended meaning.

AQ8—Please check whether all the tables are OK as set.

AQ9—Please check whether the edit conveys the intended meaning.

AQ10—Please expand PCR.

AQ11—Tables have been renumbered to ensure sequential order in the text, please confirm.

AQ12—Please check whether the edit conveys the intended meaning.

AQ13—Please check whether the meaning of the sentence "Treatment of the 20 breasts…" is OK as meant.

AQ14—Please check whether the edit conveys the intended meaning.

AQ15—Please check whether the phrase "Baker Score no detectable" is OK or can be revised to "Baker Score not detectable."

AQ16—Please check whether "mScore" in "Baker mScore" as given in the sentence "Fourteen breasts in 13 patients …" is OK.

AQ17—Please check whether the edit conveys the intended meaning.

AQ18—Please check whether the edit conveys the intended meaning.

AQ19—Please check whether the genotype expression Arg25/Arg25 is OK or should be revised to Arg25Arg.

AQ20—Please check whether the edit conveys the intended meaning.

AUTHOR QUERIES

AUTHOR PLEASE ANSWER ALL QUERIES

AQ21—Please check whether TGF-β1 is OK as set or has to be italicized in the text.

AQ22—Please check whether the edit conveys the intended meaning.

AQ23—Please check whether the affiliations are Ok as set.